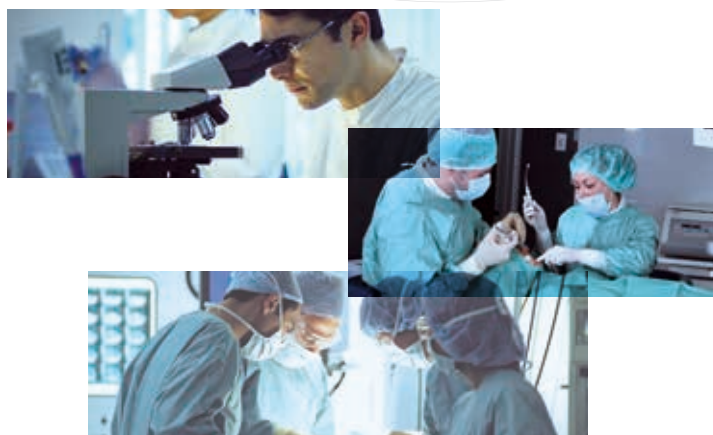

# STUDY RESULTS

# ICX-templant®

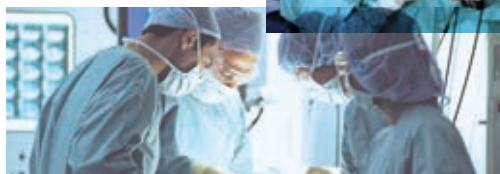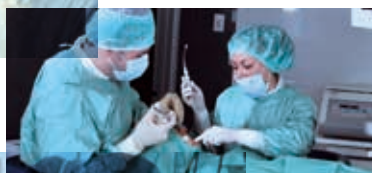(planned and ongoing studies  
and user reports – up to 08/2018)



# STUDY RESULTS

# ICX-templant®

(planned and ongoing studies  
and user reports – up to 08/2018)



# Content

## Introduction

Clinical studies with the ICX-templant Implant system .....	4
---	---

## Retrospective Studies

Results of a 2-years study of the ICX-templant in clinical praxis .....	5-6
A retrospective study on the probability of success of two different diameter-reduced implant systems .....	7-8
MKG-Abutments for immediate interims restoration .....	9-10

## Prospective Studies

Complete edentulous rehabilitation with immediate function and „All-On-Four“ concept .....	11-12
Prospective randomised cross-over study for the oral quality of life in mandibular edentulous patients with a two versus four locator-retained overdenture .....	13
Orthodontic-implant treatment of congenital absence of the lateral incisors germ in the maxilla with the use of short implants .....	14
Immediate implant loading in augmented upper and lower jaw.....	15

## Experimental in vitro and in vivo studies

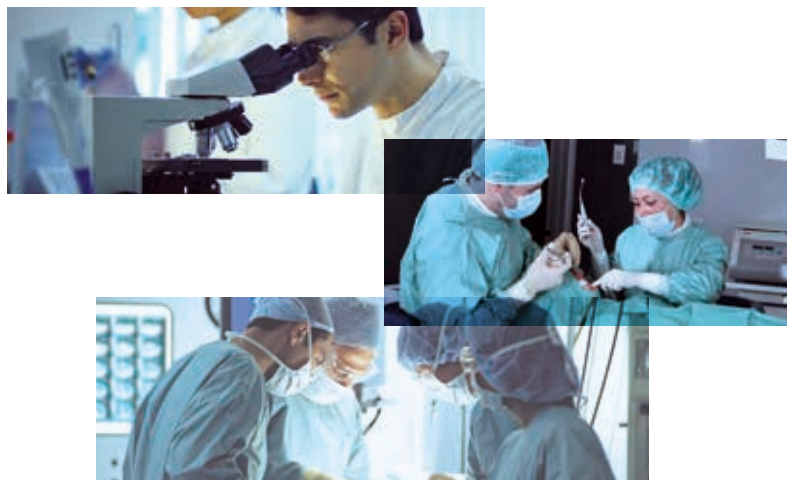In-vitro performance of titanium implants/adhesive bases with zirconia sleeves.....	17
Healing at implant sites prepared conventionally or by means of Sonosurgery. An experimental study in dogs.....	18
Subcrestal positioning of implants results in higher bony crest resorption: an experimental study in dogs .....	19
Sequential healing at implants with different configuration and modified surfaces. An experimental study in the dog.....	20
Planned and ongoing studies .....	21
Reference list .....	22

# Clinical studies with the ICX-templant Implant system

The present list of publications on the ICX-templant implant system provides a systematic survey on studies which document the preclinical and clinical application of the ICX-templant implant system. In the first part of our abstract summary you will find publications which document the long-term success of the implant system. Other chapters present articles, publications etc. regarding the stable situation of peri-implant hard and soft tissue during a treatment with the ICX-templant implant system. They are followed by articles on the prosthetic treatment of the ICX-templant implant system. Subsequent to the documentation of the successful clinical application, the chapter of the abstract folder covers preclinical studies (in vitro and in vivo). Moreover, you will find data on the ICX-templant implant system surface.

The present abstract folder aims at a transparent scientific backup of the successful use of the ICX-templant implant system and the ICX-templant implant surface. It also offers support regarding the search for relevant articles on the ICX-templant implant system. Medentis Implants has briefly summarised all the articles and informations related to the ICX-templant implant system in the abstract folder on the following pages. The original studies can be accessed at the specified source. Please contact us for a separate abstract folder with case study examples.

*For additional information, please contact your medentis implants partner or [info@medentis.de](mailto:info@medentis.de). We will be pleased to assist you.*



# ICX

*The FAIR Implant-System*

# Retrospective Studies

Table 1 Retrospective Studies

Study-No.	Page	Study Location/Year	Timepoint Follow-up in months		Number of subjects	Number of Implants	Survival Rate %	
1	5	University Aachen, 2011	36		94	413	99.27	
		<b>Results</b>	The ICX System allows almost unlimited prosthetic indications with a quite good success rate of 99,27%.					
2	7	University Köln, 2010	14	31	37	114	98.2	96
		<b>Results</b>	Due to the use of small-diameter implants from the ICX System, dental practitioners can forgo a lateral augmentation when treating patients with reduced bone width.					
3	9	Center of healthcare Willehad, 2010	10		27	108	99.1	
		<b>Results</b>	The ICX System with the MKG- abutments provides an efficient, simple and economic possibility to supply the patient without any prosthetic limitations.					

## 1) Results of a 2-years study of the ICX-templant in clinical praxis <sup>1</sup>

Prof. Dr. Murat Yildirim, Univ. Aachen 2011

### Introduction:

During the last 37 years, insertion of enossal implants for the replacement of lost teeth and anchoring of dental prostheses has proven a safe and reliable procedure. As with most treatment procedures in dentistry today, dental implants not only involve scientific discovery, research and understanding, but also application in clinical practice. The practice of implant dentistry requires expertise in planning, surgery and tooth restoration.

### Objective:

The aim of the study was to evaluate the ICX-templant® implant system company medentis medical GmbH, Dernau, Germany) in clinical praxis including both prosthetics and surgical requirements.

### Material und Methods:

This user trial includes the insertion of 413 implants as well as the adjacent prosthetic procedure. 173 (42%) implants are inserted in the upper jaw and 240 (58%) implants in the lower jaw. The study population includes 94 patients. The target populations were patients with finished growth and therefore with an indication for an implant prosthetic rehabilitation. The selection was based on the regular admission of the Clinic for Dental Prosthetics. Exclusion criteria are the absolute contra-indications for implant-surgery treatments.

Based on medical indication, the patients were subjected to immediate or conventional loading (up to 6 months healing period). The study was conducted over an obser-

# Retrospective Studies

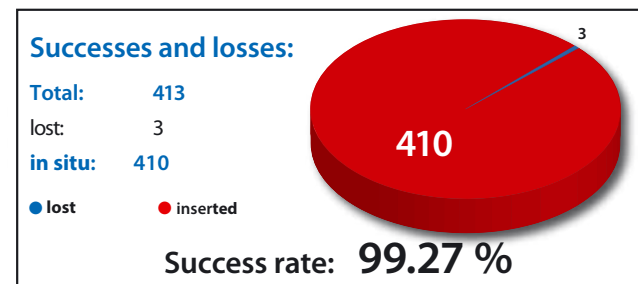
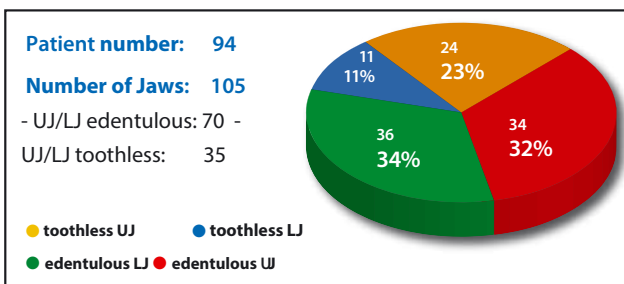
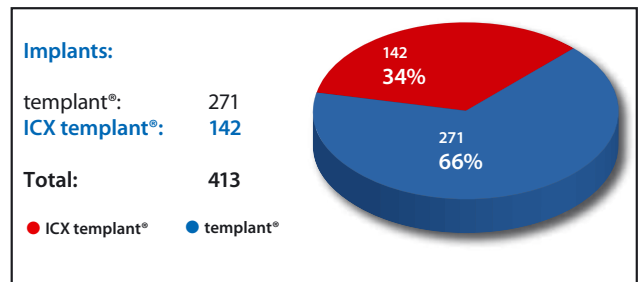
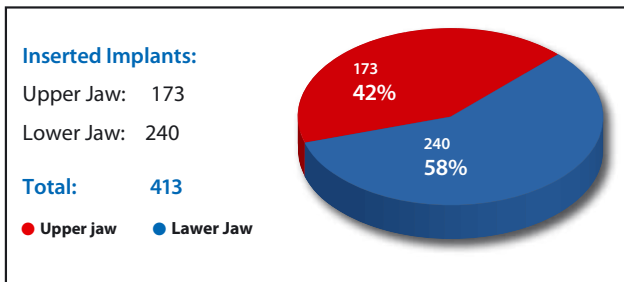
vation period of two years. A radiographic post control was performed at 6, 12, 18, and 24 months after insertion.

## Results:

3 implants of a total of 413 inserted implants did not osseointegrate. This is equivalent to a success rate of 99.27%.

## Conclusion:

The ICX-templant® represents an established standard restoration method in dentistry with an outstanding price/performance ratio.



## Figure:

Graphic evaluation of the user study (data source Yildirim 2011, see reference list)

# ICX

The FAIR Implant-System



## 2) A retrospective study on the probability of success of two different diameter-reduced implant systems<sup>2</sup>

V. E. Karapetian, M. Roels, J. Neugebauer, J. E. Zöller

### Introduction:

The aim of this study was to retrospectively determine a probability of success of two implant systems (templant<sup>®</sup> and XIVE<sup>®</sup>) with a reduced diameter. A reduced diameter means a small contact area of the implant to the bone. Furthermore, the success of narrow implants (2,8-3.8 mm-diameter) compared to standard (> 3,8 mm diameter) implants was compared.

### Material and methods:

Over a 14 month (ICX-templant<sup>®</sup> implant) and 93 month period (XIVE<sup>®</sup>-implants<sup>®</sup>), 469 narrow implants were inser-

ted in 108 patients to support partial fixed prostheses and single-tooth crowns. Clinical and radiographic assessment data were provided. The total number of 355 XIVE-implants<sup>®</sup> was followed-up. 114 templant-implants<sup>®</sup> were checked to find the survival rate. Cumulative survival and success rates were calculated with life-table analyses processed by collecting clinical and radiographic data.

### Results:

2 of 114 templant-implants<sup>®</sup> (1.8%) failed. Cumulative survival and success rates were calculated with life-table analyses processed by collecting clinical and radiographic

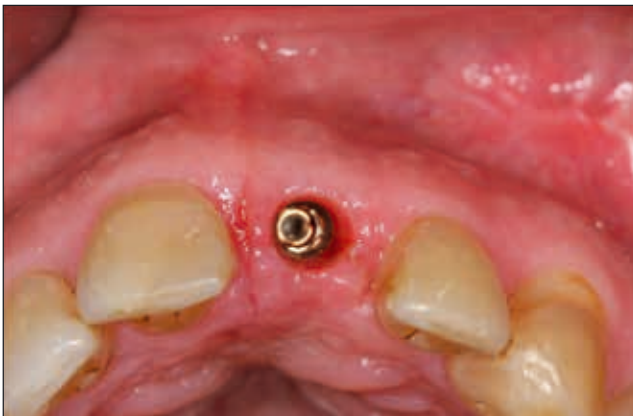

Figure 1: Opening of the implant regio 21

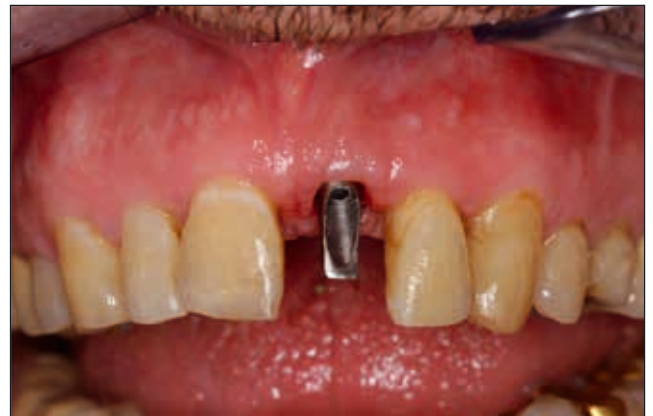

Figure 2: Abutment and implant regio 21

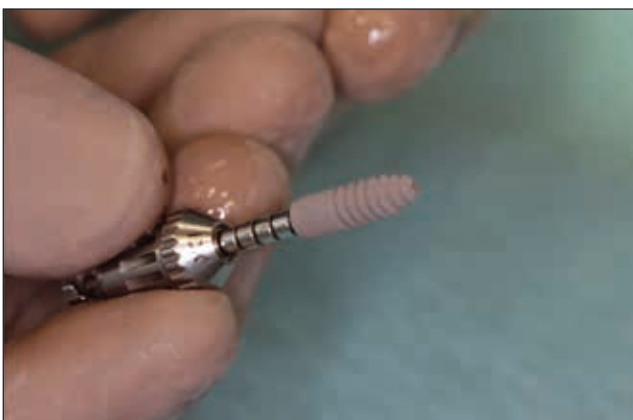

Figure 3: ICX-templant<sup>®</sup> Implant

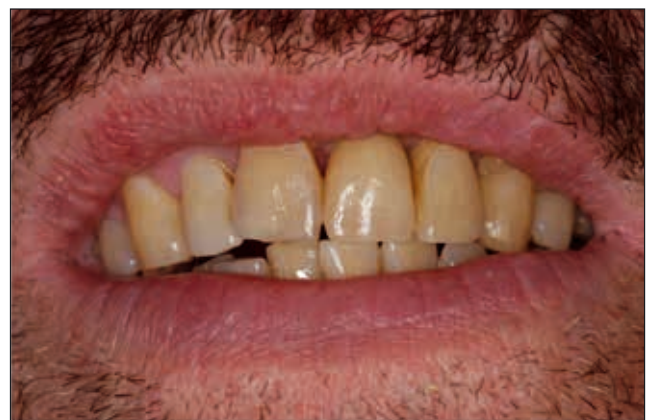

Figure 4: Final situation withn Cerec<sup>®</sup>-Crown

Figure: Insertion of an ICX-templant Implant (Data source Karapetian et. al. 2010, see reference list)

# Retrospective Studies

data. After 14 months, cumulative survival rates of 98.2% (14 months) templant-implants® and 98.6 % (93 months) XiVE-implants® were found. Survival and success rates of the two implant systems did not hold statistically significant differences ( $P > 0.05$ ).

templant® (n = 114)	N=114	%
in situ	112	98.2
explanted	2	1.8
<b>Failure reason</b>		
Losening due to lack of osseointegration	2	1.8

*Figure: Insertion of ICX-templant Implantates (Data source Karapetian et. al. 2010, see reference list)*

## Conclusion:

These results suggest that there seems to be no difference between narrow and standard diameter implants regarding the osseointegration. By using a small-diameter implant on patients with reduced bone width, dental practitioner can forgo a lateral augmentation, which presents an important advantage in implant dentistry.

XiVE® (n = 355)	n=355	%
in situ	350	98.6
explanted	5	1.4
<b>Failure reason</b>		
Losening due to lack of osseointegration	3	0.8
Peri-implantitis	2	0.6

*Figure: Frequency of implant losses and causes of failure with XiVE®-implants.*



*Presented by Karapetian (see Reference list)*

**ICX**  
The FAIR Implant-System



## 3) MKG-Abutments for immediate interims restoration<sup>3</sup>

R. Fangmann, C. Picht

### **Introduction:**

The acceptance of immediate loading protocols as a viable therapeutic alternative under certain circumstances has been increased in the last years. The goal of an immediate loading protocol is to reduce the number of surgical interventions and shorten the time frame between surgery and prosthetic delivery, all without sacrificing implant success rates. Inclusion criteria are e.g. patients completely edentulous in the atrophic mandible. One-stage surgical procedures have successfully eliminated second-stage surgery with excellent clinical results, which thereby avoids the physical trauma and chair time of the uncovering procedure. A challenge that still confronts dentists and patients alike, however, is the traditional lag time between implant placement and prosthetic loading.

### **Objective:**

The aim was to implement a method for immediate prosthetic restoration by applying the teamwork concept and additionally meeting the prosthetic and surgical requirements e.g. primary splinting and the avoidance of micro- and macromovements in the osseointegration phase.

### **Material and methods:**

Transgingival healing and immediate loading with a soft lined full denture was applied. The implantation procedure was prepared according to standard protocols. Denture was prepared after wound closure and alginate printing. An interims denture with appropriate basal space was prepared for the MKG (maxillofacial)- abutments. The denture was equipped with soft remaining relining material at the basal side.

Wounds were checked and the relining material was renewed after one week. After two further weeks, the stitches were removed and the soft remaining relining material was replaced. This procedure was repeated in the 6th post operative week. Telescope restorations on the ICX-Meso-Telescope-titanium abutment and locator restorations on implants were used in the final operation phase.

The ICX-Meso-Telescope-titanium abutment is suitable for the ICX-MKG (maxillofacial) abutment (medentis medical GmbH). After the 10th post operative week, a final prosthetic restoration by the implantologist was executable. This section describes the case of a patient treated with ICX-templant® implants on conventional locators after 12 weeks of implant insertion. To the author's knowledge, no other appropriate system on the market is available to the ICX-MKG (maxillofacial).

### **Results:**

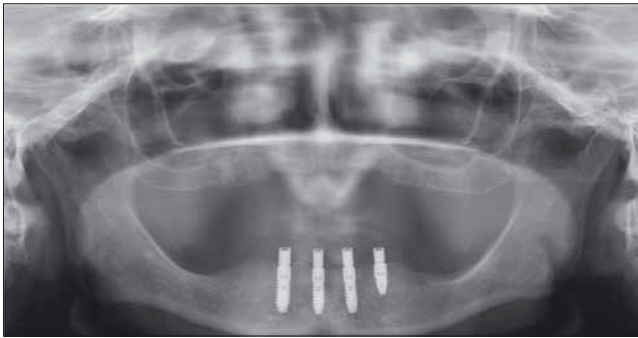
A total of 13 patients received 52 ICX-templant® implants and the corresponding MKG-abutments (4 implants and abutments per patient), which were treated immediately in the intraforaminal region. Patients were between 66,98 ± 7,62 years old. The diameter of ICX-templant implants was at 4.1 mm (58%) and 12.5 mm length (75%). Depending on the mucosa type, the MKG abutment was used in two heights, 5 mm and 7mm, respectively. 6 months after implant insertion i.e. 3 months after locator restoration as a definitive prosthetic rehabilitation, post radiographic images were taken. No bone resorption was detected immediately after implantation procedure. Since the MKG abutment was presented, the described method was ap-

# Retrospective Studies

plied by 13 dentists offering prosthetic support. 3, 25 ± 1, 71 patients were treated with implants per praxis. A total of 27 patients were treated according to this procedure. Based on the teamwork concept 4 implants were used intraforaminally – by 108 implants in total. One implant was lost during the prosthetic procedure. Telescope restorations were placed in 20 patients and locator restoration in 7 patients. Radiographic follow up images did not reveal any bone resorption at the implant shoulder.

## **Conclusion:**

MKG-abutments allow an immediate prosthetic restoration considering the teamwork concept (surgical procedure and prosthetic delivery on the same). Benefits for patients are immediate permanent dental restorations. The benefits for the implantologist are having a useful tool for planning and assessment of the final prosthetic restoration.



## **Image:**

*Orthopantogramm 10 months after operation  
(Data source Fangmann 2010, see reference list)*

**ICX**  
The FAIR Implant-System

# Prospective Studies

Table 2 Prospective Studies

Study-No.	Page	Study Location/Year	Timepoint Follow-up in months	Number of subjects	Number of Implants	Survival Rate %
4	11	University Istanbul, 2014	12	13	52	–
		<b>Results</b>	The OCC System is a good alternative treatment in fixed prosthetic rehabilitation of complete edentulous jaws.			
5	13	University Mainz, 2014	6	30	120	98
		<b>Results</b>	Patients with implant retained overdentures proved to benefit in their OHRQoL in comparison to a conventional denture.			
6	14	University Posen, 2013	–	20	48	–
		<b>Results</b>	The ICX System is easy to handle and capable for a modern prosthetic restoration.			
7	15	University Köln, 2005	3	20		77.25 ISQ (Implant Stability Quotient)
		<b>Results</b>	The ICX-system permits the immediate loading treatment method in augmented upper and lower jaws treatment technique without any problems, if you follow the surgical and prosthetic protocol.			

Further prospective clinical studies applying the ICX Templant implantsystem are planned or ongoing. The clinical study protocols are designed for maximum assessment and evaluation of the ICX Templant implantsystem in clinical praxis.

## 4) Complete edentulous rehabilitation with immediate function and “All-On-Four” concept <sup>4</sup>

P. Karasu, F. Ugurlu, A. Sertgöz

### Objective:

The aim of the study is to test the primary stability via the All on four concept by Nobel Biocare, Göteborg, Sweden [13]. The OCC kit by medentis medical GmbH is a prosthetic concept for immediate restoration of edentulous maxilla.

### Materials and Methods:

Implant placements were determined by initial volumetric tomography and implant planning program. A Gutta-perka marked base plate was fabricated as a template for indicating exact implant positions and inclinations during volumetric tomography and surgery. Also, a specially designed surgical guide was used to facilitate correct implant tilting and precise positioning of the implants in relation to the opposing jaw. 13 patients with a mean age of 55.3 (range 33 to 68) were treated with an immediately loaded fixed prosthesis supported by the „all-on-four“ concept.

Implant placements were determined by initial volumetric tomography and implant planning program.

A total of 88 implants were inserted. For each patient, two implants in anterior region were placed perpendicular to the horizontal plane and two implants in posterior region had 30-40° angulations. To meet the inclination of posterior implants 30-40° abutments were used. Immediate prosthetic rehabilitation after surgery was supplied by modification of existing total dentures and using temporary screw retained abutments. Implant stabilities were measured weekly by Osstell Mentor device until eighth week and 6 and 12 months later. Marginal bone loss was measured on periapical radiographies taken in operation, after six and twelve months. Permanent screw-retained metal-fused-porcelain or metal-resin restorations were performed at third month.

# Prospective Studies

## **Result:**

At a time frame of six months, ISQ for the maxilla were from 75 to 89 and for the mandible from 65 to 75. Based on literature data [14-16], high initial stability (ISQ values of 70 and above) tends not to increase over time despite the fact that the initial high mechanical stability decreases and is replaced by increased biological stability. Lower initial stability normally increases with time because the lower mechanical stability is increased by the bone remodeling process (osseointegration). Values of ISQ 55 or lower should be taken as a warning sign and actions to improve the stability should be considered (larger implant diameter, longer healing time, etc.).

Literature data collected from osstell provides good indications that the acceptable stability range lies between 55 and 85 ISQ, with an average ISQ level of 70.

## **Conclusion:**

Due to maximum usage of residual bone, reduced cantilever length and larger inter-implant distance „all-on-four“ concept together with the usage of straight and tilted implants is a good alternative treatment in fixed prosthetic rehabilitation of completely edentulous jaws.



The FAIR Implant-System

## ***5) Prospective randomised cross-over study for the oral quality of life in mandibular edentulous patients with a two versus four locator-retained overdenture <sup>5</sup>***

*Karbach J. DMD, MD, DDS; Hartmann S. DMD; Jahn-Eimermacher A.; Wagner W. MD, DMD*

5-years prospective, randomized cross-over trial to compare the oral health related quality of life (OHRQoL) in patients, with locator-retained overdentures in the mandibular with two or four locators, was conducted at the University hospital of Mainz (directed by Dr. Dr. Julia Karbach). Preliminary data of the oral quality of life in patients with two or four implants incorporated in the prosthesis were presented by Prof. Dr.Dr. Winfried Wagner, Dr. Dr. Julia Karbach und Dr. Sinsa Hartmann in February 2013 at a Quality Symposium of Implantology at the University Hospital of Mainz (Germany). The preliminary results of the one year time point showed a significant increase in oral quality of life in patients (n=30) with a four implant-retained overdenture. These results were summarized in the article „A prospective randomised cross-over study for the Oral quality of life in mandibular edentulous patients with a two versus four locator-retained overdenture“. The article was accepted at the 04.10.2014 and

will be published in the International Journal of Oral & Maxillofacial Implants. Upon completion of the study all four implants have been retained in the locator-retained overdenture in every patient. 2 implants (120 implants in total) of patients with atrophied lower jaw were lost in the early osseointegration phase (survival rate after 1 year 98%). The results showed that the number of incorporated implants in the locator-retained overdenture did influence the increase of OHRQoL in the lower jaw of edentulous patients (n=30) significantly with an advantage of four implants. The survival rate was 98%. Two Implants were lost during osseointegration phase. Clinical and radiological controls are planned every year until the fifth year after the first loading, publication of the three years data are planned for this year.

## 6) Orthodontic implant treatment of congenital absence of the lateral incisors germ in the maxilla with the use of short implants<sup>6</sup>

R. Flieger, P. Kopczyński

### Introduction:

In recent years the use of intra-osseous implants has become a method of choice in the treatment of various missing teeth. Disorders of tooth development are a relatively common abnormality, which might cause complications during the development of the masticatory system and the formation of a bite. A doctor conducting the treatments necessary to reproduce missing teeth should have adequate knowledge about the changes to the development and its impact on the embedded implant and have the ability to plan appropriate prosthetic work.

### Objective:

The aim of this study was to evaluate the effectiveness of short implants in difficult atrophic conditions during implantation, in the maxilla and mandible, at soft bone conditions. The thesis presents the clinical case of the fifteen-year-old patient with congenital loss of a lateral incisor who was treated with the ICX-templant implant system.

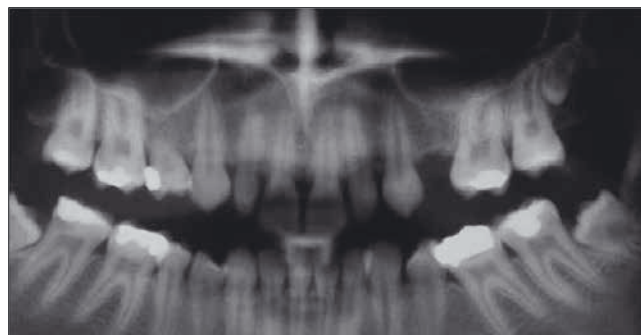
### Materials and Methods:

Clinical examination, confirmed with X-ray verification revealed the lack of the left incisor tooth in the maxilla. Intraoral examination revealed a distoposition of tooth 22. The patient commenced an orthodontic treatment with fixed thin archwire appliance aiming to reconstruct the place where an implant could be inserted at the end of the orthodontic therapy. The space in the oral cavity between tooth 21 and tooth 23 was wide enough after 14 months of treatment. A subsequent panoramic X-ray was performed to thoroughly evaluate the available size of the implantation site. Analysis concerning the arrangement of teeth revealed a decreased interradicular space between tooth 21 and tooth 23, despite using mesialising bends on the orthodontic arch and changing position of the lock on tooth 21. Due to the aforementioned, the team of implantology specialists decided to choose a

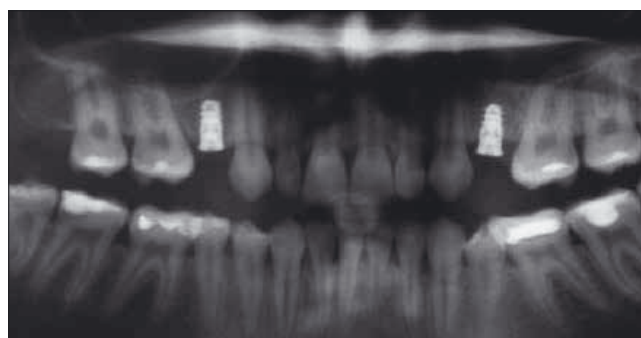
short implant from the ICX templant system, which was 6.45mm long, had a diameter equalling 3.45mm and was characterized by a unique 1.7mm long intragingival collar that simultaneously stood as an element of the future prosthetic connection. After using the last osseous drill, an inspection of the drilled part was performed with periodontal probe, which confirmed presence of only bone limitations to the implant bed. The implant was implemented according to the ICX system protocol, based on minimally invasive limited plate technique with applied torque reaching 40Nm, which led to high initial stabilization of an implant. The Lumen of the implant was sealed with a closing screw. Digital panoramic X-ray was performed after the procedure.

### Results:

The study presents. The healing time and osseointegration



**Figure:** Panoramic X-ray before treatment (Data source Flieger und Kopczyński 2013, see reference list)



**Figure:** Panoramic X-ray after implantation (Data source Flieger und Kopczyński 2013, see reference list)



period did not reveal any complications and lasted 3 months.

## **Conclusion:**

Numerous studies show that the use of modern implant systems, like the ICX-templant implant system, next to observing minimally invasive surgical protocol limits recommendations concerning tissue-augmenting procedures and using long implants or standard implants. Due

to unique features presented by ICX implants, including special osteotomic thread, microporosity, hydrophilic surface, platform switching or internal conical connections, it can be declared that an implant based rehabilitation of congenital teeth losses with short implants stands as a predictable, effective and modern treatment method.

## **7) Immediate implant loading in augmented upper and lower jaw <sup>7</sup>**

*VE. Karapetian, J. Neugebauer J, JE. Zöllner*

### **Introduction:**

Immediate loading in lower jaw is a common treatment method today. Immediate loading implants after hipbone graft, let alone immediate loading of implants in the upper jaw with and without hipbone grafting have not been examined. The quality of implant sites prepared by bone grafts varies depending on the kind of the grafting material. The evaluation of the mechanical stability was done by the RFA method (Osstell, Integration Diagnostic Inc).

### **Objective:**

The aim of this study was to show the success of immediate loading in upper and lower jaw and to compare success rates with and without hipbone graft. Primary stability and mechanical interlocking are stated as success factors for osseointegration. Also it will be investigated, immediately loaded implants show comparable stability in the upper jaw without and after hipbone grafting.

### **Materials and methods:**

To evaluate the implant stability of immediately loaded implants compared to delayed loaded implants a group of 10 patients each was examined after implantation and 3 months after prosthetic loading. Within the group of immediately loaded patients we implanted a minimum of six implants in the upper and/or 4 implants in the lower jaw. If the mean insertion torque of the implants within one bar reconstruction was higher than 35 Ncm, immediate loading was performed and the bar-supported denture was inserted few hours post-operationem.

### **Results:**

Comparison of the data did not show significant differences in implant stability between the regular loaded implant and the immediately loaded implants at implant placement and at recall. A mean of 77.25 ISQ (Implant Stability Quotient) was found in the immediately loaded group for the lower jaw implants and 70.53 ISQ in the upper jaw, compared to 75.67 ISQ in the upper and 83.50 ISQ for the lower jaw after 3 months of loading. Furthermore no clinical and radiological difference was visible. On the basis of the data collected, it can be shown that regardless of present augmentation an immediate loading can be realized with 6 connected implants in the upper and 4 connected implants in the lower jaw.

### **Conclusions:**

The treatment results showed that the immediate loading treatment method in augmented upper and lower jaws is a treatment technique without any problems, if surgical and prosthetic treatment rules are followed correctly. The primary stability of the inserted implants should not undergo the 35 Ncm insertion torque. Also it has to be mentioned that the implant length stands in no correlation to the primary stability, which is explained by the bone density. The clinical and radiological success also showed that the osseointegration of the immediately loaded implants worked in upper and lower jaw.

# Experimental in vitro and in vivo studies

Table 3 Experimental in vitro and in vivo studies

Study-No.	Page	Study Location/Year	Timepoint Follow-up in months	Number of subjects	Number of Implants	Endpoint
8	17	University Regensburg, 2014	–	In vitro	8	Static Force in Newton (N)
		<b>Results</b>	It can be assumed that the investigated systems e.g. the ICX System in most cases provides good in-vitro performance and fracture resistance			
9	18	University Sao Paulo, 2014	3	6 (Beagle)	24	BIC (Bone to Implant Contact)
		<b>Results</b>	The ICX-Gold surfaces reveal very promising Bone to Implant Contact values during the osseointegration phase.			
10	19	University Sao Paulo, 2014	2	6 (Beagle)	12	BIC (Bone to Implant Contact), ground sections
		<b>Results</b>	The ICX-templant surfaces reveal very promising Bone to Implant Contact values while osseointegration phase. Sonosurgery as a minimal invasive compromise to a conventional method is feasible with the ICX-templant implant system.			
11	20	University Sao Paulo, 2014	2	6 (Beagle)	12	BIC (Bone to Implant Contact)
		<b>Results</b>	The ICX-templant surfaces reveal very promising Bone-to-Implant Contact values during early osseointegration phase and did not reveal a significant difference between the ICX-templant and an implant system from a competitor.			



The FAIR Implant-System

## 8) In-vitro performance of titanium implants/adhesive bases with zirconia sleeves<sup>8</sup>

A. REMBS, V. PREIS, M. ROSENTRITT, M. BEHR, and C. KOLBECK, Regensburg University Medical Center, Regensburg, Germany

### **Introduction:**

In implant-supported prosthetic treatments, the choice of the restorative components and the connection system between the implants and the restorations must be considered a paramount factor for long-term success. The majority of the implant systems available today offer different types of connection between prosthetic restorations and supporting implants.

### **Objective:**

The aim of this in-vitro study was to compare the in-vitro performance and fracture resistance of implant restorations on combined titanium adhesive bases and zirconia sleeves. For the test, all systems were restored with identical zirconia crowns to simulate an anterior tooth situation.

### **Material and Methods:**

Nine commercially available screwed titanium implant-adhesive base combinations were restored with zirconia sleeves and identical full-zirconia crowns (Cercon ht, n=8 per system, tooth 11, cementation: Panavia F). For simulating clinical anterior loading situations, the implants were fixed under 135° to the tooth axis. Implant and bases varied in diameter (d=4.0 mm to 4.3 mm) and design.

Thermal cycling and mechanical loading (TC: 5x6000 cycles between 5°C/55°C, dist. water, ML: 50N for 1.2x10<sup>6</sup> cycles; f=1.6Hz; mouth opening: 2mm) with standardized antagonists was performed to simulate five years of oral service. During TCML all restorations were permanently controlled for failures. Restorations which failed during TCML were investigated in detail with scanning electron microscopy (SEM Quanta, Phillips). After TCML all restorations which survived were loaded to fracture (No. 1446, Zwick, v= 1mm/min). A standard titanium implant/abutment combination was used as a reference. Mean and standard deviation of fracture forces were calculated and statistically analysed (one-way ANOVA; α=0.05).

### **Results:**

Two systems partly showed loosening of screws during simulation between 2.000 and 3.0x10<sup>6</sup> cycles. No failures of the bonding areas were found. Fracture data varied significantly between 371.2 N and 763.03N. Titanium control showed a fracture resistance of 394.1N.

### **Conclusion:**

On basis of the in-vitro data it can be assumed that the investigated systems in most cases can provide good in-vitro performance and fracture resistance. Early re-screwing may be advised.

## 9) Healing at implant sites prepared conventionally or by means of Sonosurgery. An experimental study in dogs<sup>9</sup>

P. Vigano, D. Botticelli, LA. Salata, MT. Schweikert, J. Urbizo Velez NP. Lang

### **Introduction:**

The dynamic development of minimally invasive techniques in surgery was based on access to imaging equipment, endoscopic sets and surgeons' huge passion. Great imagination, responsibility and courage of surgeons was the driving force increasing the use of minimally invasive techniques. Looking back on the development of surgery, we can conclude that this discipline is developing in the direction for minimizing damage during the intervention. This is the reason for the development of minimally invasive techniques in surgery. With the appearance of opportunities imaging in real time, conditions were created for the performance of invasive procedures in ultrasound imaging. As an early evolved puncture techniques, which became the starting point for the development of sonosurgery.

### **Objective:**

To compare peri-implant tissue healing at implants installed in sites prepared with conventional drills or a sonic device.

### **Material and methods:**

In six Beagle dogs, the mandibular premolars and first molars were extracted bilaterally. After 3 months, full-

thickness muco-periosteal flaps were elevated and recipient sites were prepared in both sides of the mandible. In the right side (control), the osteotomies were prepared using conventional drills, while at the left side (test), a sonic device (Sonosurgery) was used. Two implants were installed in each side of the mandible. After 8 weeks of non-submerged healing, biopsies were harvested and ground sections prepared for histological evaluation.

### **Results:**

The time consumed for the osteotomies at the test was more than double compared to the conventional control sites. No statistically significant differences were found for any of the histological variables evaluated for hard and soft tissue dimensions. Although not statistically significant, slightly higher mineralized bone-to-implant contact was found at the test (65.4%) compared to the control (58.1%) sites.

### **Conclusions:**

Implant sites prepared with sonosurgery showed similar healing characteristics in osseointegration and marginal hard tissue remodeling than implant sites prepared conventionally.

## 10) Subcrestal positioning of implants results in higher bony crest resorption: an experimental study in dogs<sup>10</sup>

G. Cesaretti, NP. Lang, LA. Salata MT. Schweikert ME. G. Hernandez, D. Botticelli

The installation of an implant in a deeper position in relation to the bony crest has been suggested as a method that may contribute to maintain the hard- and soft-tissue volumes at a more coronal level in relation to the implant shoulder compared to a juxta-crestal implantation. In a recent report of an animal experiment [9], implants were installed in sites prepared with either drills or the sonic Sonosurgery device. Similar results in osseointegration and hard-tissue levels were found.

### Objective:

The aim was to compare peri-implant soft and hard tissue integration at implants installed juxta- or subcrestally. Furthermore, differences in the hard and soft peri-implant tissue dimensions at sites prepared with drills or sonic instruments were to be evaluated.

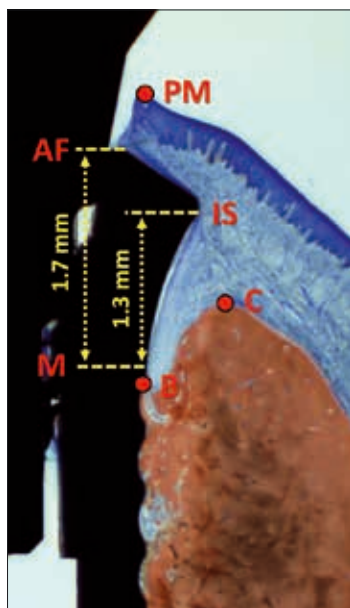
### Material and methods:

Three months after tooth extraction in six dogs, recipient sites were prepared in both sides of the mandible

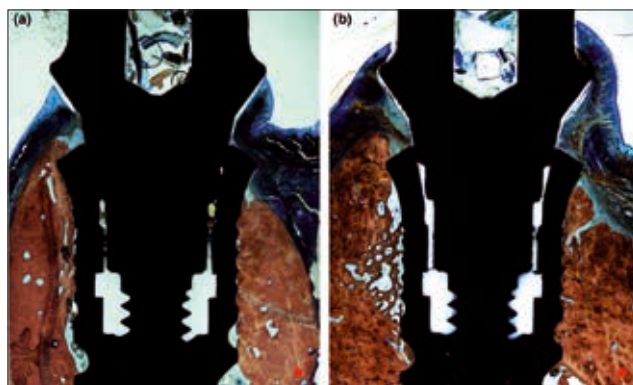
using conventional drills or a sonic device (Sonosurgery). Two implants with a 1.7-mm high-polished neck were installed, one with the rough/smooth surface interface placed at the level of the buccal bony crest (control) and the second placed 1.3 mm deeper (test). After 8 weeks of non-submerged healing, biopsies were harvested and ground sections prepared for histological evaluation.

### Results:

The buccal distances between the abutment/fixture junction (AF) and the most coronal level of osseointegration (B) were  $1.6 \pm 0.6$  and  $2.4 \pm 0.4$  mm; between AF and the top of the bony crest (C), they were  $1.4 \pm 0.4$  and  $2.2 \pm 0.2$  mm at the test and control sites, respectively. The top of the peri-implant mucosa (PM) was located more coronally at the test sites ( $1.2 \pm 0.6$  mm) compared to the control sites ( $0.6 \pm 0.5$  mm). However, when the original position of the bony crest was taken into account, a higher bone loss and a more apical position of the peri-implant mucosa resulted at the test sites.



**Figure:** Clinical view. Two implants were placed each side of the mandible. One implant (on the left) was placed with the rough/smooth coronal margin flush to the buccal bony wall (juxta-crestal). The second (on the right) was placed with the implant shoulder flush with the buccal bony wall (sub-crestal). (Data source Cesaretti et. al. 2014, see reference list)



**Figure:** Ground sections representing the healing after 8 weeks at the sub-crestal implants (Test sites). The bony crest was located at about 1.3-1.4 mm from AF at sites prepared with (a) drills or (b) Sonosurgery. Original magnification 16x. Stevenel's blue and alizarin red stain. The buccal aspects are on the right of each figure (red marks). (Data source Cesaretti et. al. 2014, see reference list)

## **Conclusions:**

The placement of implants into a sub-crestal location resulted in a higher vertical buccal bone resorption and a more apical position of the peri-implant mucosa in

relation to the level of the bony crest at implant installation. Moreover, peri-implant hard-tissue dimensions were similar at sites prepared with either drills or Sonosurgery.

## **11) Sequential healing at implants with different configuration and modified surfaces. An experimental study in the dog <sup>11</sup>**

*MT. Schweikert, D. Botticelli, L. Sbricoli, A. Antunes, V. Favero & LA. Salata*

### **Introduction:**

The sequential healing at implants installed in alveolar bone has been thoroughly described in a series of animal [17-20] and human studies [21-23]. In an experiment in dogs [18], the sequential healing of the hard tissue was studied at implants that had either a sand-blasted and acid etched or a machined surface.

### **Objective:**

The aim is to evaluate the peri-implant soft and hard tissues adaptation to implants with different modified surfaces and configurations.

### **Material and methods:**

6 Beagle dogs were used. Mandibular premolars and first molars were extracted bilaterally. After 3 months, full-thickness flaps were elevated and two different types of trans-mucosal implants (ICX-Gold® Medentis, Dernau, Germany and SLActive®, Institute Straumann, Bern, Switzerland) and two different surfaces were randomly installed in the distal regions of one side of the mandible. Abutments were applied and a non-submerged healing was allowed.

After 1 month, the procedures were performed in the other side of the mandible and after a further month, the animals were sacrificed, biopsies were collected and ground sections prepared for histological examination.

### **Results:**

Similar results in marginal bone and soft tissues dimensions were observed after one month of healing with the two implant systems used and no major changes could be observed after 2 months of healing. After one month, the percentage of new bone was 69.0% and 68.8 at ICX-Gold® and SLActive® surfaces, respectively. After two months, the percentage of new bone was 67.8% and 71.9% at ICX-Gold® and SLActive® surfaces, respectively. No statistically significant differences in osseointegration were found.

### **Conclusion:**

The two implant systems used resulted in similar osseointegration after 1 and 2 months of healing.



# Planned and ongoing studies

Two studies are planned for 2015:

1) a prospective, randomized study directed by Prof. Dr. sc. Robert Celic (University of Zagreb). Aim of this study is the comparison of conventional/early/ immediate loading of ICX-templant implants in edentulous jaws. An observation period of 5 years is planned and includes a study population of 160 patients, 500 implants and abutments.

Professor Dr. Atilla Sertgöz (University of Istanbul) will direct a prospective OCC study Follow up study applying the ICX-multi system of medentis medical GmbH.

Table 4 Planned and ongoing studies

Study Location/Year	Timepoint Follow-up in months	Number of subjects	Number of implants	Planned endpoints	Notes
University of Istanbul, 2015	12	13	52	ISQ	Follow up study with the ICX-mult system
University of Zagreb, 2015	12-60	160	500	ISQ, Success rate, orthopanthogramm, bone preservation	Comparison of conventional/early/ immediate loading of ICX-templant implants in edentulous jaws



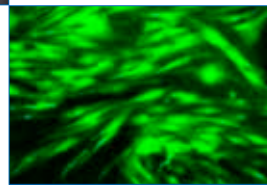

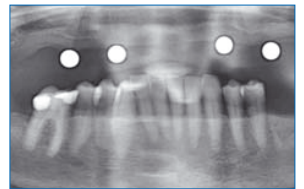


The FAIR Implant-System

## Reference list:

1. Klinische Bewährung des ICX templant®-Systems im Praxisalltag medentis medical GmbH: „2-Jahresstudie“, Dental Tribune, No. 12 Vol. 6, 11. Dezember 2009, Seite 15
2. V. E. Karapetian, M. Roels, J. Neugebauer, J. E. Zöllner Eine retrospektive Studie über die Erfolgswahrscheinlichkeit von durchmesserreduzierten Implantatsystemen Wissenschaftliches Poster Jahrestreffen der European Association of Osseointegration (EAO), Monaco, 30.09 - 03.10.2009 und beim 25. Jahrestreffen der Academy of Osseointegration (AO), Orlando, Florida, 4-6 März 2010
3. Dr. Rainer Fangmann, Cordula Picht MKG-Überweiser- Abutment für sofort belastete Interimsversorgung ZWPspezial 7+8/2010
4. Pelin Karasu, Faysal Ugurlu, Atilla Sertgöz Complete edentulous rehabilitation with immediate function and All-on-Four Concept Wissenschaftliches Poster, European Prosthodontic Association EPA, Istanbul 25. - 27. September 2014
5. Karbach J, Hartmann S, Jahn-Eimermacher A, Wagner W. Oral Health-Related Quality of Life in Edentulous Patients with Two- vs Four-Locator-Retained Mandibular Overdentures: A Prospective, Randomized, Crossover Study. *Int J Oral Maxillofac Implants*. 2015 Sep-Oct;30(5):1143-8. doi: 10.11607/jomi.3987.
6. Rafał Flieger, Przemysław Kopczyński Orthodontic-implant treatment of congenital absence of the lateral incisors germ in the maxilla with the use of short implants *Sztuka Implantologii* 2013
7. Karapetian VE, Neugebauer J, Zöllner JE: Immediate implant loading in augmented upper and lower jaw. Scientific Poster, Academy of Osseointegration Annual Meeting, March 10 - 12, 2005.
8. Rembs A, Preis V, Rosentritt M, Behr M, Kolbeck C.: „In-vitro performance of titanium implants/adhesive bases with zirconia sleeves.“ IADR Capetown 2014 oral presentation
9. Paolo Vigano. Daniele Botticelli. Luiz A. Salata. Michael T. Schweikert. Joaquin Urbizo Velez. Niklaus P. Lang. Healing at implant sites prepared conventionally or by means of Sonosurgery®. An experimental study in dogs *Clin Oral Implants Res*. 2014 Feb 13. doi: 10.1111/clr.12348
10. G. Cesaretti, NP. Lang, LA. Salata MT. Schweikert ME. G. Hernandez, D. Botticelli Sub-crestal positioning of implants results in higher bony crest resorption: an experimental study in dogs. *Clin. Oral Impl. Res*. 00, 2014, 1-6
11. Michael T. Schweikert, Daniele Botticelli, Luca Sbricoli, Antonio Antunes, Vittorio Favero & Luiz A. Salata Sequential healing at implants with different configuration and modified surfaces. An experimental study in the dog. *Clinical Implant Dentistry & Related Research* 2015 under review (Study performed by Michael T. Schweikert Cand. Dent. (La Habana, Kuba) Faculty of. Dentistry, University of Medical Science, La Habana (Kuba)
12. Przemysław Kopczyński, Rafał Flieger, Iwonna Flieger, Kornela Miś-Kopczyńska, PhD Orthodontic-implant treatment of congenital buds defects with the use of ICX templant implant system *Implantology* 2014
13. <https://www.nobelbiocare.com/nl/en/home/products-and-solutions/treatment-concepts/all-on-4.html>
14. 20 Jahre Erfahrung mit der Resonanzfrequenzanalyse Sennerby L, Sahlgrenska Academy, University of Gothenburg, Sweden *Implantologie* 2013;21(1):21-33
15. Immediate vs. early loading of SLA implants in the posterior mandible: 5-year results of randomized controlled clinical trial Kokovic V, Jung R, Feloutzis A, Todorovic V, Jurisic M, Hämmerle C *Clinical Oral Implants Research*, 00, 2013, 1-6
16. Early Loading of Nonsubmerged Titanium Implants with a Chemically Modified Sand-Blasted and Acid-Etched Surface: 6-Month Results of a Prospective Case Series Study in the Posterior Mandible Focusing on Peri-Implant Crestal Bone Changes and Implant Stability Quotient (ISQ) Values MM. Bornstein, CN. Hart, SA. Halbritter, D. Morton, D. Buser. *Clin Implant Dent Relat Res* 2009
17. Berglundh T, Abrahamsson I, Lang NP, Lindhe J. De novo alveolar bone formation adjacent to endosseous implants. *Clin Oral Implants Res*. 2003; 14:251-262.
18. Abrahamsson I, Berglundh T, Linder E, Lang NP, Lindhe J. Early bone formation adjacent to rough and turned endosseous implant surfaces. An experimental study in the dog. *Clin Oral Implants Res*. 2004; 15:381-392.
19. Buser D, Brogginini N, Wieland M, Schenk RK, Denzer AJ, Cochran DL, Hoffmann B, Lussi A, Steinemann SG. Enhanced bone apposition to a chemically modified SLA titanium surface. *J Dent Res*. 2004; 83:529-533.
20. Schwarz F, Ferrari D, Herten M, Mihatovic I, Wieland M, Sager M, Becker J. Effects of surface hydrophilicity and microtopography on early stages of soft and hard tissue integration at non-submerged titanium implants: an immunohistochemical study in dogs. *J Periodontol*. 2007; 78:2171-2184.
21. Bosshardt DD, Salvi GE, Huynh-Ba G, Ivanovski S, Donos N, Lang NP. The role of bone debris in early healing adjacent to hydrophilic and hydrophobic implant surfaces in man. *Clin Oral Implants Res*. 2011; 22:357-364.
22. Lang NP, Salvi GE, Huynh-Ba G, Ivanovski S, Donos N, Bosshardt DD. Early osseointegration to hydrophilic and hydrophobic implant surfaces in humans. *Clin Oral Implants Res*. 2011; 22:349-56.
23. Terheyden H, Lang NP, Bierbaum S, Stadlinger B. Osseointegration--communication of cells. *Clin Oral Implants Res*. 2012; 23:1127-1135.

# ICX

*The FAIR Implant-System*



**medentis**<sup>®</sup>  
medical

# STUDY RESULTS

# ICX-templant<sup>®</sup>

(planned and ongoing studies  
and user reports – up to 08/2018)

